



STRATEGIES *for* SUCCESS

WITH
TORIC &
Presbyopia-
Correcting IOLs



Precise Preoperative Planning Optimises Premium IOL Outcomes

Advanced diagnostic technologies play a key role in preoperative assessments

By Simonetta Morselli, MD

Visual outcomes from premium intraocular lenses (IOLs) depend on many factors, but precise preoperative measurements obtained with advanced diagnostic technologies form the foundation of a successful procedure.

TRENDING TECHNOLOGY

Precise measurements are especially important as more surgeons implant premium IOLs. Figure 1 shows the types of presbyopia-correcting IOLs surgeons are using, as reported in the 2017 and 2018 ESCRS Clinical Trends Surveys.

Looking to the next five years, 60% of 2018 survey respondents are most interested in integrating trifocal/quadrifocal IOLs into their practices, 59% EDOF IOLs and 24% light-adjustable IOLs. Furthermore, 32% of respondents most commonly use toric IOLs in a monofocal cataract patient with 1.25D of cylinder, 29% use on-axis incision and 21% use glasses or contact lenses.

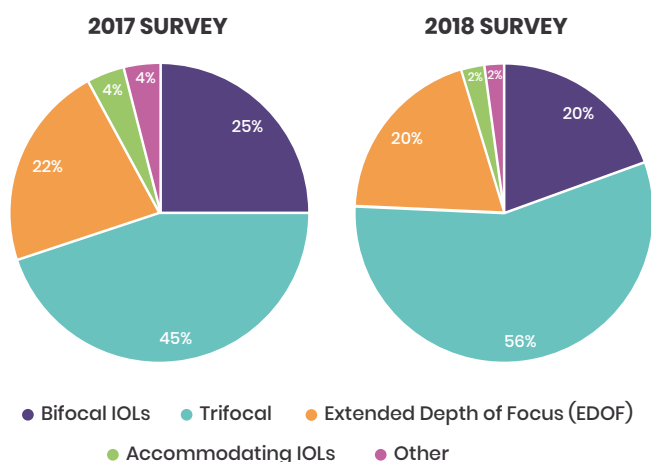


Figure 1. ESCRS 2017 and 2018 survey responses to question: *What type of presbyopia-correcting IOL technology is used in the majority of your presbyopia-correction patients?*

BUILDING ACCURATE DATA

We perform a complete ocular examination to rule out conditions that may negatively impact the patient's surgical outcome. It includes corneal topography with Scheimpflug imaging, as well as other technologies that can identify corneal abnormalities. This is followed by optical biometry.

We also use optical coherence tomography (OCT) to examine the retina. If retinal abnormalities are found, I do not implant a premium IOL. I also check for glaucoma and other abnormalities.

Figure 2 shows survey results for technologies used to obtain preoperative measurements for toric IOLs.

When measurements differ between two devices, I perform a third measurement with another device.

“A higher-power IOL that is only 0.1mm forward in the capsular bag can cause a 1.0D refractive error”

If K readings vary among three devices, for example, I investigate why. This inconsistency may be caused by ocular surface disease. I do not proceed if there are discrepancies.

Although surgeons often do not prioritise tear film assessment during preoperative examinations for cataract surgery, an inadequate tear film can impact preoperative measurements and visual outcomes.¹

Corneal topography provides information about the patient's ocular surface, but additional tests, such as tear interferometry, tear osmolarity and MMP-9, also may be performed. If the patient has ocular surface disease, we treat it and perform IOL measurements after the ocular surface is optimised.

We also take a careful patient history, including age, profession and other details, and talk with patients about their expectations. We normally exclude patients with unrealistic expectations and those who cannot understand the potential side-effects associated with premium IOLs.

ANTICIPATING CHALLENGES

Despite our best efforts, postoperatively we may find that the patient was under-corrected or over-corrected. Residual refractive errors may result from anatomic differences between patients. For example, the location of the capsular bag affects IOL position. A higher-power IOL that is only 0.1mm forward in the capsular bag can cause a 1.0D refractive error.

I use the IOLMaster (Zeiss) to perform IOL calculations. If a surgeon is unsure about a patient who has had refractive surgery, I suggest using the ASCRS IOL power calculator for eyes that have previously had LASIK, PRK or RK (<http://iolcalc.ascrs.org/>).

The 2018 ESCRS survey showed that 65% of respondents consider posterior corneal astigmatism in their toric power calculations. According to Koch et al., overlooking posterior corneal astigmatism may lead to errors in estimating total corneal astigmatism.²

Corneal topography with the Scheimpflug camera measures anterior and posterior corneal astigmatism.

Surgically induced astigmatism (SIA) generally is minimal if we use a 2mm corneal incision (typically 0.25-to-0.5D). When we implant a toric lens, the IOL calculation takes SIA into consideration.



CASE REPORT: PEARLS FOR INTRAOPERATIVE SUCCESS

Intraoperatively, we need to make the most of available technologies to ensure precise incisions and alignment of toric IOLs.

I use the femtosecond laser to create the capsulorhexis, which provides more accurate surgical results. The diameter is precise and it perfectly covers the edge of the IOL, which may reduce the risk of postoperative lens rotation.

I also recommend microincision surgery, with a 2.2mm incision, to reduce the risk of SIA, which is particularly important with premium IOLs.³

To “lock” the IOL into the capsular bag, all viscoelastic under the IOL should be removed. Then the IOL should be aligned in the correct axis. Finally, the viscoelastic should be removed

very gently, blocking the IOL with the second instrument. The patient should avoid strenuous activity for one week.

Many surgical systems include iris mapping or other features to assist the surgeon when aligning toric IOLs.

I prefer an automated marking system for toric IOLs. Comparing a digital marking system with ink marking, Webers et al. reported that the digital system resulted in less toric IOL misalignment; however, visual acuity and residual astigmatism were not impacted.⁴

The 2018 ESCRS survey showed that 46% of respondents who implant toric IOLs during cataract surgery perform ink marking with manual axial instruments; 31%, ink marking at the slit lamp without additional instruments; 17%, digital image registration; 6%, anatomical landmarks without preoperative marking; and 1% have access to intraoperative wavefront aberrometry.

If a surgeon does not have digital technology, manual marking can be performed at 12 o'clock and 6 o'clock, with alignment of a calibrated corneal marking ring at these points, which helps the surgeon implant the IOL in the correct position. — *Simonetta Morselli, MD*

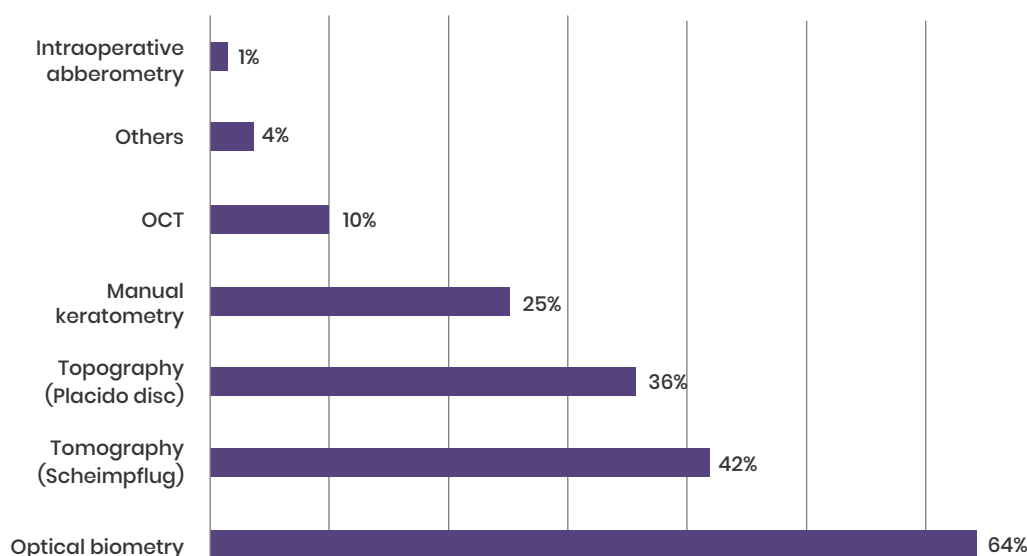


Figure 2. ESCRS 2018 survey responses to question: What are the primary preoperative measurements that drive your astigmatism axis decisions when implanting a toric IOL?

CONCLUSION

A comprehensive ocular examination is essential in preparing for cataract surgery. Today's advanced diagnostic technologies enable surgeons to obtain precise measurements that will help patients achieve optimal visual outcomes from premium IOLs.

REFERENCES

1. Epitropoulos AT, Matossian C, Berdy GJ, et al. Effect of tear osmolarity on repeatability of keratometry for cataract surgery planning. *J Cataract Refract Surg*. 2015; 41:1672–1677.
2. Koch DD, Ali SF, Weikert MP, et al. Contribution of posterior corneal astigmatism to total corneal astigmatism. *J Cataract Refract Surg*. 2012; 38:2080–2087.
3. Hayashi K, Manabe S, Yoshida M, et al. Effect of astigmatism on visual acuity in eyes with a diffractive multifocal intraocular lens. *J Cataract Refract Surg*. 2010; 36:1323–1329.
4. Webers VSC, Bauer NJC, Visser N, et al. Image-guided system versus manual marking for toric intraocular lens alignment in cataract surgery. *J Cataract Refract Surg*. 2017; 43:781–788.

“ Surgically induced astigmatism generally is minimal if we use a 2-mm corneal incision

Dr Morselli is head of the Ophthalmology Department, S. Bassiano Hospital, Bassano del Grappa, Italy. She may be contacted at simonetta.morselli@gmail.com. Dr Morselli has no financial disclosures to report.



Trifocal IOLs: Presbyopia and Astigmatism Treatment Options

Toric models enable surgeons to correct astigmatism during implantation

By Jorge Alió, MD, PhD

Today, a number of trifocal intraocular lens (IOL) technologies are available in Europe, including PanOPTix (Alcon), AT LISA tri (Zeiss) and FineVision (PhysIOL). Many offer a toric version, which is a major advantage when striving to achieve optimal visual outcomes with this lens technology.¹ Residual refractive error requiring correction is one of the main obstacles to patient satisfaction when using trifocal IOLs, so it is important to take necessary steps to achieve our target refraction.

In approximately one-third of all cases, we implant toric trifocal IOLs to correct astigmatism during surgery to avoid the need for postoperative laser vision correction for residual astigmatism.

LENS DESIGNS

The use of bifocal IOL technologies is declining, and manufacturers are using other technologies to increase patients' intermediate focus.

We have a range of trifocal IOL models, as well as panfocal IOLs. Diffractive and refractive IOLs provide good vision for near, intermediate and distance (Figure 3).^{2,3} In a meta-analysis, Xu et al. found that trifocal IOLs provided better intermediate vision than bifocal IOLs.⁴

With trifocal IOLs, light is distributed to multiple foci to achieve far, intermediate and near vision. Some designs have slightly weak near distance vision.

Extended depth of focus IOLs provide far and intermediate vision, with less near vision.⁵

MATCHING TECHNOLOGIES TO PATIENT NEEDS

I typically implant multifocal IOLs in active patients who are no older than 80 years. They usually enjoy reading and using computers, have hobbies requiring near vision and desire spectacle independence. If the patient has astigmatism greater than 1.0D, I implant a toric trifocal IOL.

I also use these lenses in children with paediatric cataracts or complications of certain diseases. If they have no other comorbidities, I believe they are excellent candidates for trifocal or multifocal IOLs rather than a

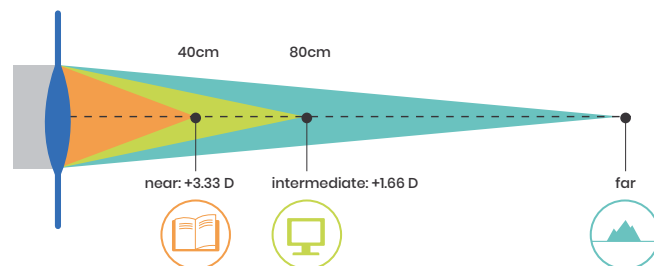


Figure 3. Trifocal IOLs have three distinct focal points for near, intermediate and far vision.

monofocal IOL because they will require near vision for their entire lives.

When implanting trifocal IOLs, patient selection is important to achieve optimal results and patient satisfaction.

First, patients must have good tear film function to obtain optimum vision quality. Secondly, we need to be sure the quality of the cornea is good, as assessed by corneal topography and corneal aberrometry, without optical aberrations, especially from previous corneal refractive surgeries.

In general, I prefer not to implant multifocal IOLs in patients who have had previous corneal refractive surgeries, although some surgeons may disagree. Fifteen or 20 years ago, LASIK and PRK were performed with lasers with different optical profiles compared with today's technologies, so many of these patients are not good candidates for multifocal IOLs. In these types of patients, other refractive technologies can be considered, such as a small-aperture IOL. As a general rule, if the patient has abnormal levels of coma and aspheric aberration (exceeding 1.0µm of total root mean square of higher-order aberrations or more than 0.3-to-0.4µm of either of these aberrations), these multifocal IOLs should not be implanted.

In addition, patients should have normal macular function and adequate visual potential. I often perform



CASE REPORT: MYOPIC ASTIGMATISM WITH NUCLEAR SCLEROSIS

A 63-year-old biology professor with myopic astigmatism had nuclear sclerosis (nuclear opacity grades 1 and 2) that impacted his work in high contrast in cell biology. He was aware of advances in multifocal IOLs, but halos could compromise his work and he desired good night driving vision.

A refractive rotational asymmetric lens was recommended. Bilateral simultaneous sequential cataract surgery was performed, with implantation of a multifocal toric +3.0D IOL because near and intermediate vision were his main visual preferences. This lens is provided in a customised cylinder and must be implanted at 12 o'clock because the cylinder is in the exact position that we ordered. The surgery was uneventful and performed with topical anaesthesia with sedation.

Three days after surgery, the patient's binocular distance vision was 0.8. Near vision was J2 with marginal levels of refraction. The patient was extremely happy with his quality of vision to define contrast, spectacle independence for all distances and improvement in his visual performance for all activities.

This case illustrates how multifocal IOLs can be selected for highly qualified persons with hypercritical personalities. A diffractive IOL was not chosen because low mesopic contrast sensitivity function could affect his research with microscopes and contrast phase meters. — **Jorge Alió, MD, PhD**

“Today’s trifocal IOLs allow surgeons to help patients achieve good near, intermediate and distance vision

optical coherence tomography of the macula to confirm the suitability of these patients for implantation of a multifocal IOL.

If patients have macular abnormalities or other comorbidities such as glaucoma, they may not be good candidates for multifocal IOLs because they will not achieve good optical performance. Some surgeons state that multifocal IOLs help patients with macular limitations or a family history of macular disease use low-vision aids, which may be true; however, multifocal IOLs decrease contrast sensitivity, which already is affected in these patients.⁶

In some cases, I also use other devices, such as potential acuity meter devices (RAM, Vryghem test) to determine whether the patient will achieve a satisfactory visual outcome.

In Europe we have refractive and diffractive models of trifocal IOLs, and I use either of them, depending on the patient profile. In my practice, approximately 65% of my patients receive multifocal IOLs. I select lens technologies based on the patient’s profile. Because diffractive technologies are associated with glare and halos at night, patients are not good candidates if they frequently drive at night. In those situations, I prefer to implant refractive IOLs.

Alternatively, refractive IOLs may cause distortion that can affect some people who work in highly illuminated environments with reflections, so they are not a beneficial choice for these patients. Low-add refractive lenses are usually well tolerated by patients in conditions that are not optimal for multifocality.

Technologies to explore and identify optical side-effects of refractive IOLs, particularly distortion, are to be developed because they are very much needed to better understand the optical behaviour of the human eye with these types of lenses.

CONCLUSION

Today’s trifocal IOLs allow surgeons to help patients achieve good near, intermediate and distance vision. To achieve optimal visual outcomes, careful patient selection, based on the absence of significant corneal anterior surface aberrations and comorbidities that decrease contrast sensitivity function with normal visual potential, is an important key to success. We also need to correct astigmatism during cataract surgery to avoid residual astigmatism to achieve a successful outcome. IOL technology should be selected by using evidence-based data.

Multifocal lenses, either refractive or diffractive, should be in the armamentarium of the modern cataract and lens surgeon.

REFERENCES

1. Gerl M, Breyer DR, Hagen P, et al. Clinical comparison of a trifocal and a trifocal-toric intraocular lens based on the same diffractive platform. *Klin Monbl Augenheilkd*. 2017; 234:1276–1282.
2. Plaza-Puche AB, Alió JL. Analysis of defocus curves of different modern multifocal intraocular lenses. *Eur J Ophthalmol*. 2016; 26:412–417.
3. Alió JL, Plaza-Puche AB, Alió Del Barrio JL, et al. Clinical outcomes with a diffractive trifocal intraocular lens. *Eur J Ophthalmol*. 2018; 28:419–424.
4. Xu Z, Cao D, Chen X, et al. Comparison of clinical performance between trifocal and bifocal intraocular lenses: a meta-analysis. *PLoS One*. 2017; 12:e0186522.
5. Cochener B, Boutillier G, Lamard M, et al. A comparative evaluation of a new generation of diffractive trifocal and extended depth of focus intraocular lenses. *J Refract Surg*. 2018; 34:507–514.
6. Plaza-Puche AB, Alió JL, Sala E, Mojzís P. Impact of low mesopic contrast sensitivity outcomes in different types of modern multifocal intraocular lenses. *Eur J Ophthalmol*. 2016; 26:612–617.

Dr Alió is professor and chairman of ophthalmology, University of Alicante, Spain. He may be contacted at jalio@vissum.com. He is a clinical research advisor for Zeiss, Alcon and Oculentis.



Range of Extended Depth of Focus IOLs Help Correct Presbyopia

EDOF IOLs are forgiving and provide specific benefits for presbyopic patients

By Francesco Carones, MD

Extended depth of focus (EDOF) intraocular lenses (IOLs) are available in Europe in a number of models.

Four of the most common are Symphony (Johnson & Johnson Vision), AT LARA (Zeiss) and Mini Well (SIFI), which each have spherical and toric options, and Lucidis (Swiss Advanced Vision), which is only available as a spherical IOL.

Two of these lenses feature diffractive steps: the

Symphony IOL has been designed to elongate the focal point through an echelette design (Figure 4) and the AT LARA takes a trifocal approach, with three focal points blending into each other to provide extended depth of focus.

In the optical design of the Mini Well, positive and negative spherical aberration are merged to elongate the depth of focus. The Lucidis has a central hyperprolate area on the optical plate, extending the focal point.

“ With EDOF IOLs, surgeons may help patients attain more spectacle independence by using mini-monovision techniques

PATIENT SCREENING

It is essential to perform a comprehensive examination before choosing an EDOF IOL, including visual acuity, manifest refraction, slit-lamp examination, ocular surface examination, keratometry, biometry, corneal topography and a complete retinal examination. We need to maintain contrast sensitivity with these lenses; therefore, the retina and macula must be perfect to achieve the best visual outcomes with EDOF IOLs.

One of the most important assessments is to determine the patient's expectations. We also need to identify reading distance for each patient. For example, some patients read at 40cm, whereas others read at 50cm. Patients still reading at 50cm because they can accommodate to some extent are very good candidates for EDOF IOLs.

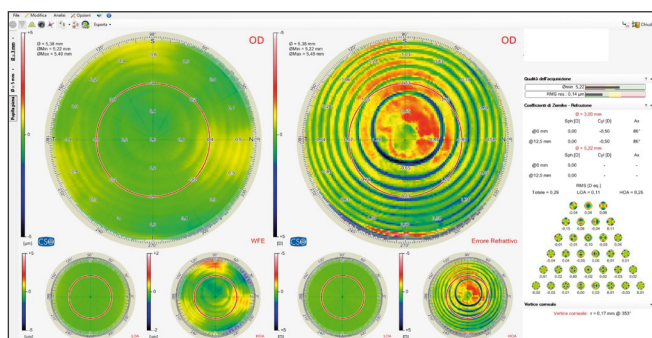


Figure 4. The image shows the total aberrometry of an eye implanted with a Symphony IOL. Note the wide range of dioptric power the diffractive echelette pattern provides.

EDOF IOLs provide very good distance and intermediate vision.¹⁻⁴ They do not provide total spectacle independence with regard to near distance, especially in dark conditions, so patients may need to use +1.0 or +1.5D reading glasses to optimise their near vision in these situations. However, they obtain good vision with reading glasses, which may not be the case with some trifocal IOL technologies. In addition, visual disturbances are less common.¹⁻⁴

Patients seeking better visual performance for distance and intermediate vision who are willing to use +1.0D reading glasses for near in certain instances are good candidates for EDOF IOLs.

EXAMINING BENEFITS

We also need to consider the features of each EDOF lens in terms of patients' expectations regarding visual quality and spectacle independence.

With EDOF IOLs, surgeons may help patients attain more spectacle independence by using mini-monovision techniques.⁴ Targeting the dominant eye as



CASE REPORT: EARLY PRESBYOPIA

A patient in his 50s with early presbyopia chose to have refractive lens exchange to correct -6.0D myopia and presbyopia. He could not comfortably read or use the

computer without spectacles.

I talked with the patient about the best solution for him and we chose an EDOF IOL.

The patient was particularly pleased with his outcome because his quality of vision is good and his intermediate and distance vision were very good. For most computer use, he does not wear glasses at all and he rarely uses the +1.0D glasses. With the +1.0D correction, he reported that he has very good, clear near vision, which does not happen routinely in previously myopic patients. Myopic patients are used to having very clear near vision before surgery, and after implantation of a presbyopic IOL they may have decreased contrast sensitivity, so they believe their quality of vision is not as good. However, in this case, he was very satisfied with his vision and vision quality.

— Francesco Carones, MD

plano and the nondominant eye as slightly myopic (from -0.5 to -0.75D) may significantly increase the patient's spectacle independence without compromising the quality of vision.

In addition, because EDOF IOLs are forgiving, I have found that patients may be more able to tolerate slight residual astigmatism and a small amount of defocus error postoperatively.

CONCLUSION

Preferences vary regarding the best IOL options for presbyopic patients. However, for surgeons who are considering presbyopia-correcting IOLs, I believe these lenses are very forgiving and provide good outcomes, even though patients may need to use low-add readers for near vision.

Surgeons who would like to offer presbyopia-correcting IOLs can provide excellent quality of vision with EDOF IOLs without significant dysphotopsia. They also can increase spectacle independence by using mini-monovision techniques with EDOF IOLs.

REFERENCES

1. Cochener B, Boutilier G, Lamard M, et al. A comparative evaluation of a new generation of diffractive trifocal and extended depth of focus intraocular lenses. *J Refract Surg.* 2018; 34:507-514.
2. Mencucci R, Favuzza E, Caporossi O, et al. Comparative analysis of visual outcomes, reading skills, contrast sensitivity, and patient satisfaction with two models of trifocal diffractive intraocular lenses and an extended range of vision intraocular lens. *Graefes Arch Clin Exp Ophthalmol.* 2018; 256:1913-1922.
3. Savini G, Schiano-Lomoriello D, Balducci N, et al. Visual performance of a new extended depth-of-focus intraocular lens compared to a distance-dominant diffractive multifocal intraocular lens. *J Refract Surg.* 2018; 34:228-235.
4. Cochener B; Concerto Study Group. Clinical outcomes of a new extended range of vision intraocular lens: international multi-centre Concerto Study. *J Cataract Refract Surg.* 2016;42:1268-1275.

Dr Carones is Medical Director and Physician CEO, Carones Vision, Milan, Italy. He can be contacted at fcarones@carones.com. He is a consultant for Johnson and Johnson Vision, Carl Zeiss Meditec and CSO.



Addressing Rotational and Residual Error After Implantation of Advanced Technology IOLs

Preoperative and postoperative steps enhance visual outcomes

By Oliver Findl, MD, MBA

Multifocal, extended depth of focus (EDOF) and toric intraocular lenses (IOLs) enable surgeons to correct presbyopia or astigmatism during cataract and refractive lens exchange surgeries. To improve patient satisfaction, surgeons need to take steps to prevent residual refractive errors and astigmatism and develop protocols to address them if they occur.

RESIDUAL ASTIGMATISM AFTER TORIC IOL IMPLANTATION

A common cause of residual astigmatism with toric IOLs is incorrect preoperative measurements. In addition, if we do not take into account posterior corneal astigmatism, our total corneal astigmatism prediction may be incorrect.¹

In addition, the toric IOL may be placed incorrectly during surgery. Furthermore, it may rotate after surgery, which generally occurs within the first few hours or the first day or two postoperatively. (See case report for my protocol for postoperative IOL rotation.)

Surgeons should not reposition the IOL too early because it may rotate again. I typically wait one week to 10 days, when the anterior and posterior capsules have collapsed around the IOL and the capsular bag is smaller.

In very rare cases, the IOL may rotate multiple times. This may occur in patients with a very asymmetric capsular bag. We may need to explant the IOL and implant a spherical IOL, addressing the astigmatism with corneal refractive surgery.

ADDRESSING OTHER RESIDUAL ERRORS

Residual errors also may be caused by incorrect biometry measurements and IOL power calculations, as well as other issues.

When I am performing preoperative measurements, if results from two devices vary, I repeat them. If there

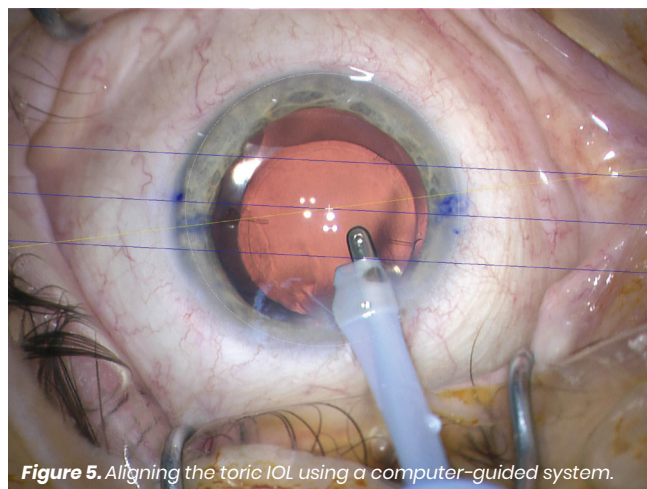


Figure 5. Aligning the toric IOL using a computer-guided system.

“A common cause of residual astigmatism with toric IOLs is incorrect preoperative measurements

are still discrepancies, the patient most likely has dry eye. I ask the patient to use artificial tears intensively and return one week later for measurements.

I also use four formulas for each eye (Barrett, Haigis, Holliday 2 and SRK/T) and compare the results. If the IOL powers are the same, I am satisfied. If they are quite different, I use the one that induces the most myopia. The likelihood of emmetropia is higher, and I



CASE REPORT: POSTOPERATIVE ROTATIONAL ERROR

In a patient with postoperative rotational error, we perform a refraction and measure the residual astigmatism. This is followed by keratometry and corneal tomography to identify postoperative changes due to surgically induced astigmatism.

I dilate the pupil and measure the IOL position at the slit lamp, comparing this with our intended axis. Because the IOL is in a different position, I use astigmatismfix.com. The software calculates how much rotation is necessary to reduce astigmatism. Figure 6 shows a sample graph using the calculator.

A problem arises when the axes calculated from the refraction and from the keratometry are different. In this situation, the refraction may not have been precise enough, which impacts the calculation. Or, the keratometry or topography also may be incorrect because of a poor tear film²; therefore, we need to optimise the tear film before performing calculations.

I use a computer-guided system for intraoperative positioning of the IOL (Figure 5) and it works well for me; however, manual marking can produce good results if it is done precisely.³

I open the previous paracentesis with an irrigating cannula. It is important to avoid using viscoelastic when rotating an IOL. Viscoelastic will re-inflate the capsular bag; after we remove it, the lens may rotate again.

I rotate the lens to the correct position using a Sinskey hook. It is a quick, minimally invasive procedure.

— Oliver Findl, MD, MBA

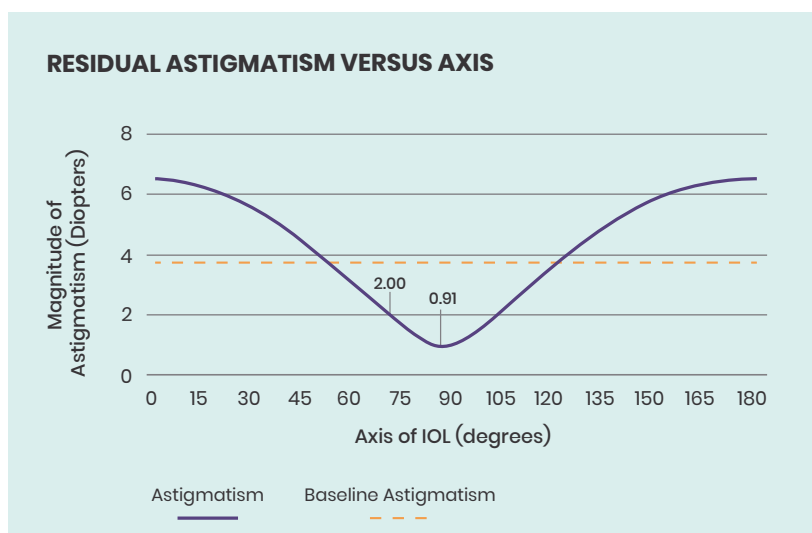


Figure 6. Example graph in astigmatismfix.com calculator showing the best possible reduction of astigmatism from 2.0D down to 0.9D with rotation of the toric IOL.

would rather patients have slight myopia than slight hyperopia. However, slight myopia will not work in patients receiving multifocal IOLs because they seek good uncorrected distance visual acuity.

For surgeons, even 0.5-to-0.75D is too much residual error. Slight myopia generally is not a significant problem, but +0.5D hyperopia is usually too much. However, some patients with +2.0 or +3.0D before surgery may be quite happy with +0.5D after surgery and may not want an additional procedure.

We have three options to correct residual spherical error. We can perform an IOL exchange, which should be done while it is easy to reopen the capsular bag. The second is to implant an add-on IOL, which is inserted into the sulcus. The third option is to perform laser refractive surgery.

I prefer an IOL exchange for significant refractive errors. If the capsule has shrink-wrapped the IOL and the lens is well positioned, I am more likely to insert an add-on lens.

Lens technology also determines how much residual error patients can tolerate. Patients with EDOF IOLs are more likely to accept refractive errors for distance because these lenses have a small plateau in the defocus curve, but intermediate vision may then be worse. With trifocal and bifocal IOLs, we need to be as close as possible to emmetropia for good functional vision.

CONCLUSION

When implanting advanced technology IOLs, we need to take steps before surgery to prevent residual error. To achieve patient satisfaction, we also need to know how to effectively correct residual errors and IOL rotation after surgery.

REFERENCES

1. Koch DD, Jenkins RB, Weikert MP, et al. Correcting astigmatism with toric intraocular lenses: effect of posterior corneal astigmatism. *J Cataract Refract Surg.* 2013; 39:1803-1809.
2. Epitropoulos AT, Matossian C, Berdy GJ, et al. Effect of tear osmolarity on repeatability of keratometry for cataract surgery planning. *J Cataract Refract Surg.* 2015; 41:1672-1677.
3. Webers VSC, Bauer NJC, Visser N, et al. Image-guided system versus manual marking for toric intraocular lens alignment in cataract surgery. *J Cataract Refract Surg.* 2017;43:781-788.

Dr Findl is chief of the Department of Ophthalmology, Vienna Hanusch Hospital, and founder of the Vienna Institute for Research in Ocular Surgery (VIROS), Austria. He may be reached at oliver@findl.at. Dr Findl is a scientific adviser to Alcon, Carl Zeiss Meditec AG, Johnson & Johnson Vision and Merck.

Supported by an unrestricted educational grant from