

IME SUPPLEMENT | FEBRUARY 2024

EUROTIMES

*The Future of
Refractive Surgery –
Lenticule Extraction,
Phakic IOLs &
Beyond*

*Beyond
Phakic IOLs &
Lenticule Extraction
Refractive Surgery
The Future of*

Independent medical education supported by
Johnson and Johnson Vision, STAAR Surgical
and Zeiss.

ESCRS Clinical Trends in Refractive Surgery

BY BÉATRICE COCHENER-LAMARD, MD, PhD

Since 2016, the European Society of Cataract and Refractive Surgeons (ESCRS) has been collecting clinical data from thousands of delegates to better understand trends and unmet needs in the treatment of refractive and cataract surgery patients¹. The most recently published ESCRS Clinical Survey was conducted in 2022 during the 40th ESCRS Annual Congress in Milan. This survey included 146 questions and over 1700 delegates participated. Some data highlights were published as an *EuroTimes* supplement² in September 2023, and another survey was launched during the 41st ESCRS Annual Congress in Vienna.

Refractive Surgery Procedures

The 7-year clinical data trend showed that after a substantial decrease from 2016 until 2020, the number of corneal refractive surgeries has been gradually increasing in the last 3 years (Figure 1). Since 2020, and post-COVID, the volume of corneal refractive surgery has increased by an average of 26 procedures annually.

What is your average ANNUAL volume of corneal refractive surgery CURRENTLY?

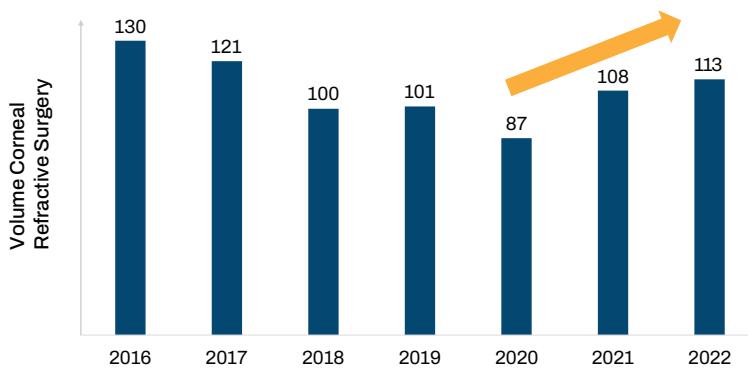
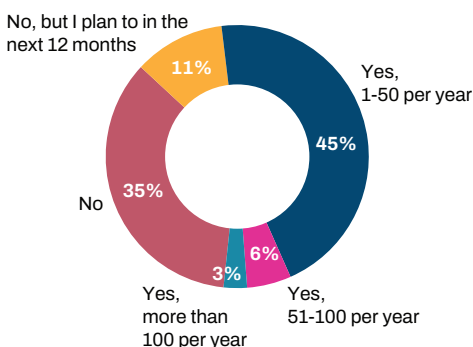


Figure 1 ESCRS Clinical Survey: 7-year data trend (2016-2022) on the average annual volume of corneal refractive surgery. Since 2020 the number of corneal refractive procedures has increased by an average of 26 annually.

The 2022 ESCRS Clinical Survey further asked delegates what was the mostly commonly performed corneal refractive procedure in their practice. 24% of respondents reported that most of their corneal refractive procedures were wavefront-optimized, 24% were mostly performing standard ablations, and only 12% reported femtosecond intrastromal lenticule extraction as their most used corneal refractive procedure. Albeit not new, lenticule extraction is still a relatively novel approach, similarly to phakic IOLs. However, both have the potential of redefining conventional refractive surgery. Expanding the range of refractive surgery, phakic IOLs are currently implanted by 54% of delegates and 11% plan to in the next 12 months (Figure 2). While 35% of the delegates report that they are not implanting phakic IOLs and have no plans to do so in the near future.

Do you CURRENTLY implant phakic IOLs?



While 35% of the delegates report that they are not implanting phakic IOLs and have no plans to do so in the near future.

Figure 2 2022 ESCRS Clinical Survey Data on phakic IOLs usage. 46% of the respondents currently do not implant phakic IOLs.

Ocular Surface and Dry Eye

Dry eye symptoms following laser vision correction are a frequent concern. Dry eye does negatively impact visual performance, although it is not always reported by the patients. The 2022 ESCRS Clinical Survey data shows that on average 17% of the laser vision correction patients experience dry eye after the procedure.

“Don’t forget the ocular surface when you’re considering refractive surgery!”

Thus, when considering refractive surgery diagnosing and managing the ocular surface is critical. Yet, the 2022 ESCRS Clinical Survey showed that only 64% of the delegates are systematically checking the ocular surface in all their preoperative laser vision correction examinations. It is, therefore, essential that more delegates acknowledge this unmet need and incorporate ocular surface evaluation into their preoperative workflow for all refractive surgery patients.

As new technologies become available the 2023 and future annual ESCRS Trends Surveys will be quite revealing on their clinical impact.



Béatrice Cochener-Lamard, MD, PhD, is Dean at Faculty of Medicine and Health Sciences, University of Bretagne Occidentale, Brest, France and former president of ESCRS. Prof. Dr. Cochener-Lamard can be contacted at beatrice.cochener@ophthalmologie-chu29.fr

REFERENCES

1. Kohonen, T., Findl, O., Nuijts, R., Ribeiro, F. & Cochener-Lamard, B. ESCRS Clinical Trends Survey 2016-2021: 6-year assessment of practice patterns among society delegates. *J Cataract Refract Surg* 49, 133-141 (2023).
2. IME Supplement: ESCRS Clinical Trends Survey 2022 Results. *EuroTimes* (2023).

The Reemergence of Refractive Surgery

BY VICTOR DERHARTUNIAN, MD

According to the World Health Organization (WHO), refractive error is one of the leading causes of visual impairment and blindness, globally¹. Refractive surgery encompasses any surgical procedure that aims to correct or minimize refractive errors^{2,3}. Beyond the traditional laser refractive surgery, a broader selection of options is now available to treat a wider range of refractive errors.

Patient Perceived Barriers

Most refractive procedures have been established as safe and effective, however some patients continue to express concern about safety, outcomes and cost when considering refractive surgery. There is worry about postoperative dry eye, visual symptoms, such as glares, halos, and starbursts or flap-related complications and corneal ectasia. Albeit, corneal ectasia is rare, it's one of the most devastating postoperative complications.

Postoperative dry eye symptoms however, are recognized as fairly common. Interestingly, the 2022 ESCRS Clinical Trends Survey indicated that on average 17% of the patients experience dry eye symptoms after laser surgery but only 6% of the patients experience dry eye symptoms following lenticule extraction (LE). It is well-known that while LASIK is generally safe and effective it does have a greater impact on corneal anatomy than LE⁴. Dry eye symptoms after LE are less severe and usually faster to recover.

Better Diagnostics

Over the years considerable improvements have been made in corneal diagnostics, from Placido technology to Scheimpflug imaging (Figure 1), even 3D cornea scans and the anterior segment optical coherence tomography (AS-OCT) with epithelial mapping are now available. Software has improved and more precise screening methods have been introduced, such as the Belin-Ambrosio screening or artificial intelligence that has also been critical to the introduction of keratoconus screening and automated dry eye screening,

which are now much more commonly available. So, due to better diagnostics there is better patient selection, leading to fewer potential postoperative problems.

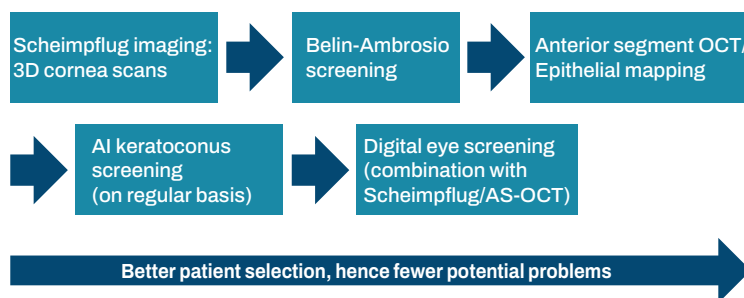


Figure 1 Better diagnostics lead to better patient selection and fewer potential problems postoperatively.

Improved Technology

Laser vision correction has come a long way since the introduction of the excimer laser surgery in 1987 (Figure 2). At that time, safety was much lower and there were numerous side effects and a longer visual rehabilitation, mostly improved by the introduction of LASIK in 1991, wavefront technology in 1999, and Femto-LASIK in 2001. Dry eye symptoms in particular, were improved with the introduction of the first generation of LE in 2011. Centration and cyclorotation control in the second generation of LE further improved visual quality and treatment precision. Noticeably, with all these technological developments visual quality improved and complications decreased.

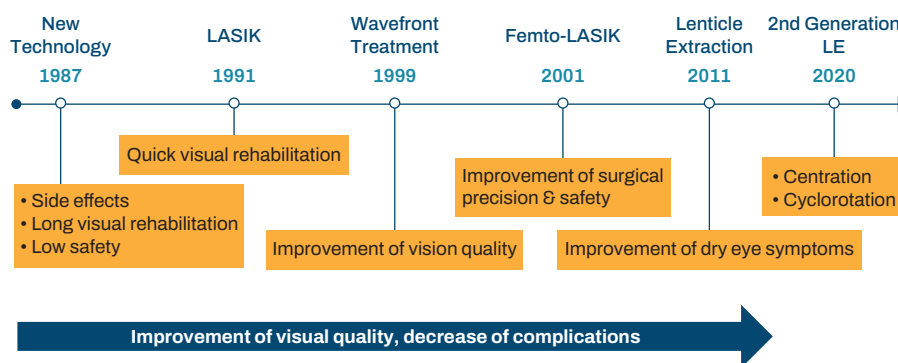


Figure 2 Technological developments in refractive surgery have improved visual quality and decreased complications.

Lenticule Extraction

Lenticule extraction is an effective, safe, and predictable treatment for myopia, myopic astigmatism, and soon also hyperopia. This minimally invasive procedure is performed through a small surgical incision of around 2-4 mm. LE offers good spherical aberration control and creates a large functional optical zone, which can potentially provide better postoperative visual quality and induce fewer higher order ocular aberrations. Altogether, LE procedure results in high refractive predictability, efficacy, safety, hence improved visual quality and quality of life for the patient.

Phakic IOLs

Another option to address a variety of refractive errors in patients where laser treatments may not be suitable are phakic IOLs (pIOLs), which have also been refined substantially in recent years. In the past, a variety of angle-supported phakic IOLs existed on the market, however most of them disappeared due to high complication rates. The two main lens types currently available are iris-supported pIOLs and sulcus-supported pIOLs (ICL type). Long term anatomical complications decreased with the improvement of the architecture of these lenses, namely material and anatomy, for example, with the introduction of the ICL aqua-port. On the other hand, preoperative diagnostics improved with the use of UBM to measure sulcus-to-sulcus distance or ciliary body-to-ciliary body and the anterior segment OCT in combination with regression formulas (LASSO), allowing better vault prediction, leading to fewer long-term complications and a lower occurrence of cataract induction.

“We have a refractive solution for about 99% of patients. We just need to choose the right treatment!”

pIOLs are an additive technology that expands the range of refractive surgery to cover higher degrees of myopia, astigmatism, hyperopia, and, more recently, presbyopia. Phakic IOLs are fully reversible and do not impact the corneal surface.

Conclusions

While LASIK/femto-LASIK remains the gold standard for treating visual defects, a patient with dry eye concerns might be a better candidate for pIOLs or LE. In patients with corneas at risk, which can be recognized through good diagnostics, laser surgery might not be performed, but rather a pIOL implanted. Currently, there are refractive solutions for 99% of patients, but it is important that the right treatment is chosen. Hence it is imperative to discuss safety profiles and outcomes with the patients to select the right procedure.



Victor Derhartunian, MD is a refractive surgeon at EyeLaser Clinics in Vienna, Austria and Zurich, Switzerland, and at SwissLaser Clinics in Poland. He is a consultant for Schwind Eye-Tech-Solutions. Dr. Derhartunian can be contacted at vd@eyelaser.at.

REFERENCES:

- <https://www.who.int/news-room/fact-sheets/detail/blindness-and-visual-impairment>.
- Kim, T. im, del Barrio, J. L. A., Wilkins, M., Cochener, B. & Ang, M. Refractive surgery. *The Lancet* 393, 2085–2098 (2019).
- Ang, M. et al. Refractive surgery beyond 2020. *Eye* 2020 35:2 35, 362–382 (2020).
- Kobashi, H., Kamiya, K. & Shimizu, K. Dry Eye After Small Incision Lenticule Extraction and Femtosecond Laser-Assisted LASIK: Meta-Analysis. *Cornea* 36, 85–91 (2017).

New Data in Lenticule Extraction

BY ROHIT SHETTY, DNB, FRCS, FACS, FWCRS, PhD

Younger patients interested in refractive surgery often have many requirements such as precise vision in diverse environments, fast recovery time and minimal side effects like dry eye symptoms post-surgery. A non-flap based refractive surgery like lenticule extraction (LE) can address these requirements. Yet patients may still be apprehensive and express some concerns regarding quality of vision, high-definition contrast, challenges in dim light settings, and dry eye.

Based on a patient’s specific visual demands and lifestyle a LE procedure should be considered. There are currently a few options available, one being the new Smooth Incision Lenticule Keratomileusis (SILK) procedure, performed on the ELITA platform. This refractive procedure involves three major surgical steps: initial docking (Figure 1A), creation of a biconvex lenticule with the femtosecond laser (Figure 1B), dissection of the anterior and posterior segments, and lenticule extraction (Figure 1C).

A week after the procedure patients demonstrate exceptional visual quality at 20/10, exhibits good optical quality on the Optical Quality Analysis System (OQAS), and displays a good Modulation Transfer Function (MTF), indicating good contrast and sensitivity.

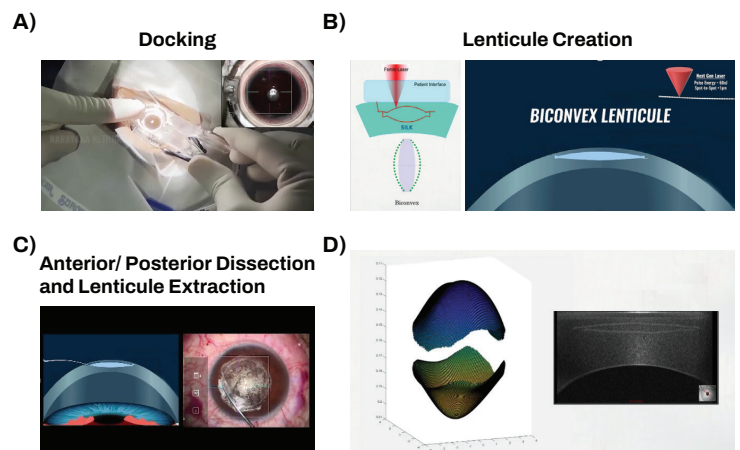


Figure 1 Lenticule extraction procedure (SILK) on the ELITA platform. Main surgical steps: A) docking, B) biconvex lenticule creation, C) anterior/posterior dissection, and lenticule extraction. D) 3D reconstruction of lenticule profile, using ASOCT maps. (Courtesy of Dr. Shetty.)

Reasons Behind Good Outcomes with Refractive Corneal Lenticule Extraction

The outcome of the SILK lenticule extraction procedure with the ELITA isn’t solely determined by the quality of the

lasers or the surgeon skills; it relies also on how the procedure works on the ocular tissues, particularly the Bowman's layer. Bowman's layer is a strong and non-renewable acellular structure between the epithelium and the stroma. When undisturbed, the Bowman's layer is an indication of excellent vision. However, when wrinkles develop the Bowman's layer becomes irregular, which can result in irregular optics and subsequent poor quality of vision. Irregular Bowman's layer may be one of the major reasons for patient dissatisfaction.

Using ASOCT maps, the 3D reconstruction of the lenticule profile can be done (Figure 1D), which allows the assessment of both anterior and posterior structures of the lenticule (Figure 1D). The smoothness of the lenticule has a strong impact on the overall quality of vision. Minimal changes in spherical aberrations (SA) from preoperative values are responsible for good depth perception, which gives the patient a "perfect" night vision. In a comparative study using different refractive surgeries the effect of minimal change in SA on depth of focus was investigated using emmetropic individuals as reference¹. The measure of a successful refractive surgery was determined by how well the patient's vision after surgery matched with that of an emmetropic individual, someone who had never worn glasses throughout their life. After lenticule extraction with the ELITA, the depth of focus is very similar to the emmetropic eye.

"Patients who undergo lenticule extraction show faster corneal nerve regeneration, which can positively influence tear film optics."

Laser energy and shape of the lenticule have also an impact on how the nerves regenerate. Patients who undergo the SILK lenticule extraction procedure show faster corneal nerve regeneration, which can positively influence tear film optics. A regular epithelium with no irregularity or thickening after lenticule extraction results in reduced incidence of post-operative dry eye, which translates into better visual quality.

Key Features of an Ideal Lenticule Extraction Procedure

In an ideal lenticule extraction procedure key features include: 1) fast corneal nerve regeneration and resulting tear film optics, 2) minimal change in tear film breakup time (TBUT), 3) post-operative depth of focus mirroring the emmetropic

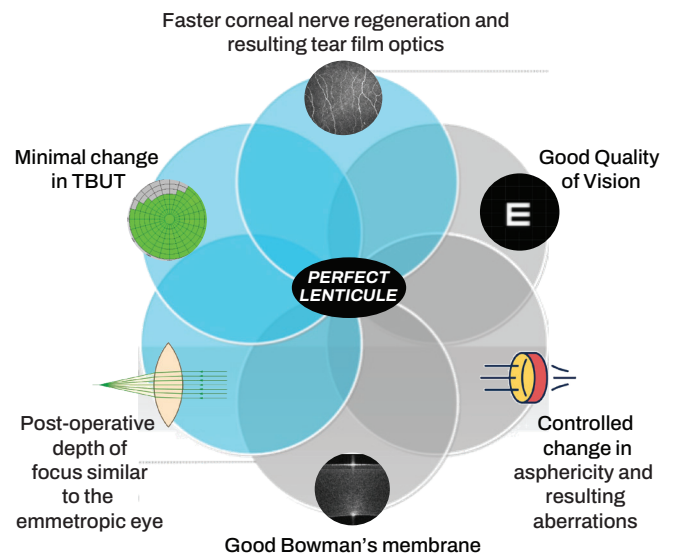


Figure 2 Overview of lenticular extraction features with the ELITA platform. (Courtesy of Dr. Shetty.)

eye, 3) well-preserved Bowman's membrane, 4) controlled change in asphericity and resulting aberrations, and 5) good quality of vision (Figure 2).

While different laser platforms have distinct qualities, whether it's the laser speed, the lenticule shape or its impact on the Bowman's layer and corneal nerves, they all have the potential to yield excellent results and to improve patients' vision and quality of life.



Rohit Shetty, DNB, FRCS, FACS, FWCRC, PhD is a clinical and translational scientist at the Department of Cornea and Refractive Surgery, Narayana Nethralaya, Bangalore, India and GROW Research Laboratory, Narayana Nethralaya Foundation, and faculty at Department of Ophthalmology, University of Maastricht, Maastricht, Netherlands. He has received research grants from Carl Zeiss, Alcon Surgical, Allergan, Novartis, Johnson and Johnson, ICMR, and DBT. Dr. Shetty can be contacted at drrohitshetty@yahoo.com.

REFERENCES:

- Shetty, N. et al. Status of Residual Refractive Error, Ocular Aberrations, and Accommodation After Myopic LASIK, SMILE, and TransPRK. *J Refract Surg* 35, 624–631 (2019).

Is Lenticule Extraction Ready for Hyperopia?

BY WALTER SEKUNDO, MD

The small incision lenticule extraction (SMILE) procedure was first introduced in 2010 to correct myopia and myopic astigmatism¹. While the myopic treatments were very successful the hyperopic treatments had a much tougher start. The results of the first hyperopic FLEx study published in 2013 were not particularly good for reasons that were not clear at that time². The efficacy was low, stability was

only acceptable and there was a major problem: substantial refractive regression over time, which was later postulated as being attributed to the small size of the transition zone³. In 2016 the profile was improved using a larger adjustable transition zone similar to the profiles used in the last-generation excimer lasers³, which, indeed, resulted in less regression and better refractive and predicted outcomes. A follow-up study

conducted in 2018 further showed the predictability and refractive outcomes of the procedure; 70% of the eyes were treated within $\pm 0.50D$ and 89% of eyes within $\pm 1.00D$ of intended correction⁴.

“Hyperopia is the next step for lenticule extraction.”

The first hyperopic SMILE study was done by Dr. Pradhan in Nepal⁵. Unfortunately, the mean spherical equivalent of the population was extremely high leading to very mixed results. Nevertheless, the Nepal study was very important in terms of optical zone centration awareness. Centration is particularly critical in hyperopia treatments. Myopia laser treatments are much more forgiving to centration. While deviations of up to 0.50mm in myopic patients are usually disregarded, hyperopic patients do notice those ranges of decentration. Subsequent studies revealed that the optimal optical zone of hyperopic lenticule extraction is 6.3mm, which corresponds to a 7mm zone with LASIK^{6,7}. This is the zone that should be aimed for.

In 2022, a prospective multicenter study included 374 eyes of 199 patients treated by SMILE for hyperopia, with and without astigmatism⁸ (Figure 1). In this study, 219 eyes were aimed for plano so the eyes were intentionally not over-corrected (Figure 1A). At 12 months, 68.8% of these eyes had an uncorrected distance visual acuity of 20/20 or better. The safety was excellent, with a total of 1.2% of eyes which lost two or more lines of corrected distance visual acuity (CDVA). It’s important to note that it is more common in hyperopia correction treatments, particularly in higher numbers, to lose one line of CDVA. The predictability was acceptable, but some dropouts were noticed, particularly toward higher corrections. To account for this factor, nomograms are in planning stages to incorporate needed adjustments. Nevertheless, in the prospective multicenter study 81% of eyes treated were within $\pm 0.50D$ and 93% of eyes were within $\pm 1.00D$ of intended correction, which is an excellent result for hyperopia (Figure 1B). The stability was also found to be good with some

regression even after 9 months. Whether this is because of late epithelial healing or just progression of presbyopia is still unclear. Patients treated for hyperopia are often in their late 30s or 40s.

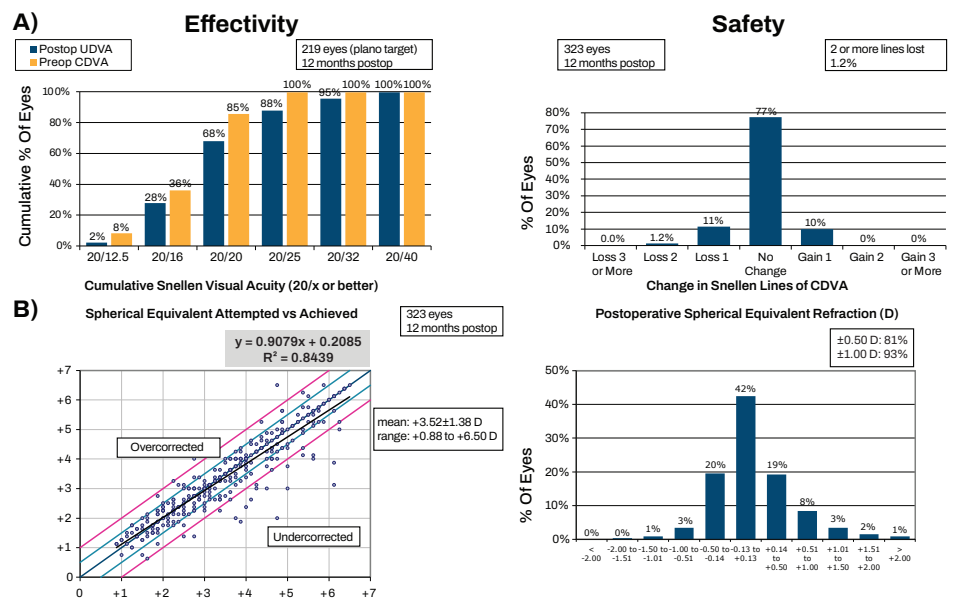


Figure 1 Lenticule extraction (SMILE) for hyperopia with and without astigmatism: A) Effectivity and safety of the procedure, B) Spherical equivalent attempted versus achieved and postoperative spherical equivalent refraction. (Adapted from⁸.)

Critical Issues with Lenticule Extraction for Hyperopia

As hyperopic eyes are small, their corneas are often also small with white-to-white diameter sometimes down to 11.5 mm. While myopic SMILE is usually performed with the S-size treatment pack, the hyperopic SMILE requires M-size treatment pack due to the large size of the lenticule (usually 8.3 mm). The combination bares an increasing risk of conjunctival aspiration and suction loss. Furthermore, this risk is increased by the longer laser time, which is approximately 35 seconds with the 500 Hz FS laser. Suction loss rate for hyperopic lenticule extraction was 0.7% (1:150 eyes) while for routine myopic lenticule extraction with SMILE it’s 0.3% (1:330 eyes). In fact, the overall suction loss in the multicenter study was as high as 1.34%. The solution for hyperopic lenticule extraction procedure with SMILE is the 2 MHz VisuMax 800 (Figure 2), which is 3x faster, which means that a hyperopic lenticule extraction takes 12 seconds with this laser platform. In addition, the new laser comes with centration and cyclotorsion assisting tools, which are of imperative significance for hyperopic treatments. The integration of hyperopic lenticule extraction into the new VisuMax 800 will provide a new excellent option for laser vision correction of hyperopia and hyperopic astigmatism.

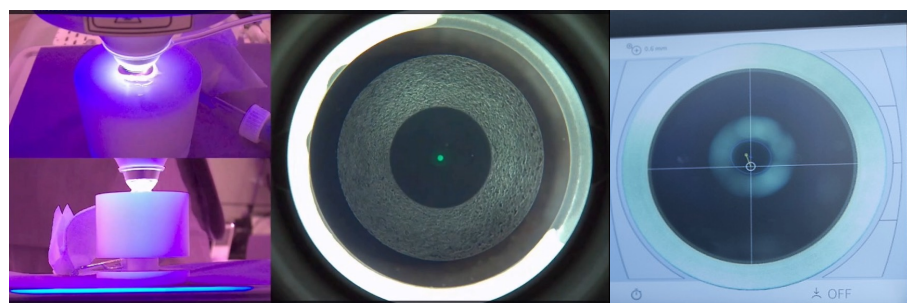


Figure 2 VisuMax 800 with 2MHz laser. (Courtesy of Dr. Sekundo.)

It's important to consider that certain platforms have a more extensive presence, accumulating more experience. Meanwhile, newer platforms are well-positioned to catch up quickly by leveraging existing foundations, but presently are focused on myopic treatments only. Ultimately, the differences may become minute and the focus will shift to the overarching concept.



Walter Sekundo, MD is full university professor of ophthalmology and chairman at the Department of Ophthalmology, Philipps University of Marburg, Germany and a consultant to Carl Zeiss Meditec AG. Dr. Sekundo can be contacted at sekundo@med.uni-marburg.de.

REFERENCES:

1. Sekundo, W., Kunert, K. S. & Blum, M. Small incision corneal refractive surgery using the small incision lenticule extraction (SMILE) procedure for the correction of myopia and myopic astigmatism: results of a 6 month prospective study. *Br J Ophthalmol* 95, 335–339 (2011).
2. Blum, M., Kunert, K. S., Vobmerbäumer, U. & Sekundo, W. Femtosecond lenticule extraction (ReLEx) for correction of hyperopia - first results. *Graefes Arch Clin Exp Ophthalmol* 251, 349–355 (2013).
3. Sekundo, W., Reinstein, D. Z. & Blum, M. Improved lenticule shape for hyperopic femtosecond lenticule extraction (ReLEx FLEx): a pilot study. *Lasers Med Sci* 31, 659–664 (2016).
4. Sekundo, W., Messerschmidt-Roth, A., Reinstein, D. Z., Archer, T. J. & Blum, M. Femtosecond Lenticule Extraction (FLEx) for Spherocylindrical Hyperopia Using New Profiles. *J Refract Surg* 34, 6–10 (2018).
5. Pradhan, K. R., Reinstein, D. Z., Carp, G. I., Archer, T. J. & Dhungana, P. Small Incision Lenticule Extraction (SMILE) for Hyperopia: 12-Month Refractive and Visual Outcomes. *J Refract Surg* 35, 442–450 (2019).
6. Reinstein, D. Z. et al. Small Incision Lenticule Extraction (SMILE) for Hyperopia: Optical Zone Centration. *J Refract Surg* 33, 150–156 (2017).
7. Reinstein, D. Z. et al. Small Incision Lenticule Extraction (SMILE) for Hyperopia: Optical Zone Diameter and Spherical Aberration Induction. *J Refract Surg* 33, 370–376 (2017).
8. Reinstein, D. Z. et al. SMILE for Hyperopia With and Without Astigmatism: Results of a Prospective Multicenter 12-Month Study. *J Refract Surg* 38, 760–769 (2022).

Modern Phakic IOLs for Myopia Correction

BY ROGER ZALDIVAR, MD, MBA

Myopia is a global epidemic. The number of people affected by myopia continue to increase and it is projected to affect 50% of the world population by 2050, meaning almost 5 billion myopes, including around 1 billion people with high myopia (≥ 6 D)¹. Another worldwide issue is contact lens dropouts^{2,3}. Around 6 million frequent contact lenses wearers dropout yearly in the USA alone.

Modern Phakic IOL Design

Phakic intraocular lenses (pIOLs) have been extensively used for the correction of different degrees of myopia and astigmatism. One of the most widely used posterior chamber pIOL is the Implantable Collamer Lens (ICL). This lens is made of a unique collagen co-polymer that provides UV protection. Most importantly, this modern pIOLs has a central port that facilitates flow of the aqueous humor through the lens, effectively eliminating the need for peripheral iridotomies. These new design elements have improved the overall safety profile and have simplified the surgical technique. The recovery is quick and the visual outcomes are good^{4,5}. The procedure doesn't cause dry eye syndrome⁶ and is reversible, if needed.

Safety and Effectiveness

Safety and efficacy are always critical aspects to consider. Since the redesign of the collamer posterior chamber phakic refractive lenses with a central flow design in 2011, no cataract procedures caused by the touch of the anterior lens capsule have been reported⁷. In terms of efficacy, it is important to highlight the ability of this platform to win lines of corrected distance visual acuity (CDVA). The six-month results of a multicenter clinical trial performed under the United States FDA Investigational Device Exemption that enrolled 629 eyes of 327 myopes showed that 52.3% of eyes gained lines of CDVA and 98.5% of eyes demonstrated CDVA at 6 months equal to or better than preoperative CDVA⁸. Impressively, at 6 months the safety index was 1.24 and the efficacy index was 1.06. Recently, a single-center, prospective, registry-based study with subjects with low (0 to -6D), moderate (-6 to -10D), and high myopia (>10D) also showed a significant line gain in best corrected visual acuity, particularly among eyes with higher degrees of myopia (Figure 1)⁹. Remarkably, some high myopes gained 4 to 5 lines postoperatively.

Line gain according to baseline SE (% baseline)

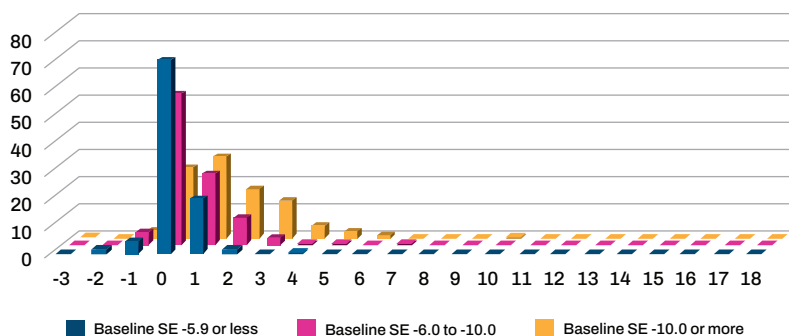


Figure 1 Postoperative line gain according to baseline spherical equivalent (SE, in diopters) in patients with low (blue), moderate (magenta), and high myopia (orange) after posterior chamber phakic implantable collamer lens surgery. (Adapted from Figure 2 in ⁹.)

Patient Selection and Preoperative Considerations

Implantation of pIOLs can be performed in patients with a wide range of myopia with or without astigmatism (SE >-1D to -20D). It's always important to assure a sufficient anterior chamber depth (≥ 3 mm from endo) to properly fit the lens, check intraoperative pressure (IOP) and signs for glaucoma, and for patients to have a stable refractive history, i.e., within 0.5D change for SE and cylinder in the last 12 months.

“The good thing about this procedure is the wide variety of options for the patients!”

One of the most important parameters to be assessed when implanting a pIOL is the measurement of the lens vault. Measurement of the internal anatomy of the eye through ultrasound biomicroscopy (UBM) seems to be an essential measure for lens size selection, which is critical to avoid low or high vault values. Performing high-resolution UBM exam in every single patient is, therefore, critical. There are currently different platforms available that can provide valuable anatomical information allowing detailed assessment of the pIOL when implanted and imaging of the ciliary body. A prospective, single-arm, observational study carried out at the Instituto Zaldivar SA (Mendoza, Argentina) using a

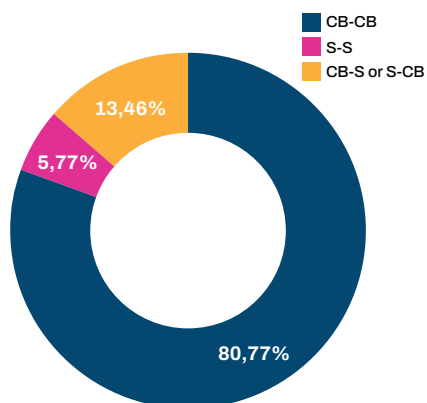


Figure 2 Pie chart depicting the frequencies, as percentage, of each of the implantable collamer lens positions in a sample of 52 eyes. CB-ciliary body, S-sulcus. (Adapted from ¹⁰).

very-high-frequency digital ultrasound robotic scanner in a sample of 52 eyes implanted with a pIOL, showed that in 81% of the cases, the lens rested on the ciliary body in both temporal and nasal sides (Figure 2)¹⁰. A better understanding of the pIOL fitting is crucial to customize formulas to more accurately predict lens location. The more accurate we can make this prediction the more confident surgeons will feel when performing the procedure.

Procedure Tips with a Posterior Chamber Implantable Collamer Lens

1. It's important not to make a too small incision, which can result in the flipping of the pIOL.
2. The use of low weight/viscosity dispersive 2% hydroxypropylmethylcellulose (HPMC) is recommended. This viscoelastic has unique properties that provide an easier flow through small openings or around the lens in the trabecular meshwork.
3. Have the right instruments to carefully grab the lens and have full control of the pIOL position. It is very important to avoid flipping the lens!
4. Always proceed with the proximal part of the pIOL first and then the distal part.
5. Don't over-aspirate the center part of the lens! This can create turbulence through the central flow and lead to cataract formation. A gentle aspiration is advised, and with circular movements.

Phakic IOL implantation is a very safe and efficacious procedure that is still in the beginning. Nevertheless, this is a refractive procedure that is rapidly growing.



Roger Zaldivar, MD, MBA is the CEO of the Instituto Zaldivar in Mendoza, Argentina. He served as a consultant for Johnson & Johnson Vision, Alcon, BVI, AcuFocus, SCHWIND eye-tech-solutions, TELEON, REVAI CARE, STAAR Surgical, Oculus, and Tracey. Dr. Zaldivar can be contacted at zaldivarroger@gmail.com.

REFERENCES:

1. Holden, B. A. et al. Global Prevalence of Myopia and High Myopia and Temporal Trends from 2000 through 2050. *Ophthalmology* 123, 1036–42 (2016).
2. Pucker, A. D. & Tichenor, A. A. A Review of Contact Lens Dropout. *Clin Optim (Auckl)* 12, 85–94 (2020).
3. Rumpakis, J. New Data on Contact Lens Dropouts: An International Perspective. *Review of Optometry* 147, 37–42 (2010).
4. Igarashi, A., Kamiya, K., Shimizu, K. & Komatsu, M. Visual performance after implantable collamer lens implantation and wavefront-guided laser in situ keratomileusis for high myopia. *Am J Ophthalmol* 148, (2009).
5. Martínez-Plaza, E. et al. Effect of the EVO+ Visian Phakic Implantable Collamer Lens on Visual Performance and Quality of Vision and Life. *Am J Ophthalmol* 226, 117–125 (2021).
6. Ganesh, S., Brar, S. & Pawar, A. Matched population comparison of visual outcomes and patient satisfaction between 3 modalities for the correction of low to moderate myopic astigmatism. *Clin Ophthalmol* 11, 1253–1263 (2017).
7. Packer, M. The Implantable Collamer Lens with a central port: review of the literature. *Clin Ophthalmol* 12, 2427–2438 (2018).
8. Packer, M. Evaluation of the EVO/EVO+ Sphere and Toric Visian ICL: Six Month Results from the United States Food and Drug Administration Clinical Trial. *Clin Ophthalmol* 16, 1541–1553 (2022).
9. Zaldivar, R., Zaldivar, R., Gordillo, C. H. & Adamek, P. Visual Acuity Improvement in Low, Moderate and High Myopia After Posterior-Chamber Phakic Implantable Collamer Lens Surgery in a Large Patient Cohort. *Clin Ophthalmol* 17, 1179–1185 (2023).
10. Zaldivar, R., Zaldivar, R., Adamek, P., Quintero, G. & Cerviño, A. Descriptive Analysis of Footplate Position After Myopic Implantable Collamer Lens Implantation Using a Very High-Frequency Ultrasound Robotic Scanner. *Clin Ophthalmol* 16, 3993–4001 (2022).